

Lower Esophageal Sphincter Augmentation for Gastroesophageal Reflux Disease: The Safety of a Modern Implant

C. Daniel Smith, MD,¹ Robert A. Ganz, MD,² John C. Lipham, MD,³
Reginald C. Bell, MD,⁴ and David W. Rattner, MD⁵

Abstract

Introduction: Use of the magnetic sphincter augmentation device (MSAD) for gastroesophageal reflux disease (GERD) is increasing. As this innovative treatment for GERD gains widespread use and adoption, an assessment of its safety since U.S. market introduction is presented.

Methods: Events were collected from the Manufacturer and User Facility Device Experience (MAUDE) database, which reports events submitted to the Food and Drug Administration (FDA) of suspected device-associated deaths, serious injuries, and malfunctions. The reporting period was from March 22, 2012 (FDA approval) through May 31, 2016, and included only events occurring in the United States. Additional information was provided by the manufacturer, allowing calculation of implant rates and durations.

Results: An estimated 3283 patients underwent magnetic sphincter augmentation (165 surgeons at 191 institutions). The median implant duration was 1.4 years, with 1016 patients implanted for at least 2 years. No deaths, life-threatening events, or device malfunctions were reported. The overall rate of device removal was 2.7% (89/3283). The most common reasons for device removal were dysphagia (52/89) and persistent reflux symptoms (19/89). Removal for erosion and migration was 0.15% (5/3283) and 0% (0/3283), respectively. There were no perforations. Of the device removals, 57.3% (51/89) occurred <1 year after implant, 30.3% (27/89) between 1 and 2 years, and 12.4% (11/89) >2 years after implant. The rate of device removal and erosion with an implant duration >2 years were 1.1% (11/1016) and 0.1% (1/1016), respectively. All device removals and erosions were managed nonemergently, with no complications or long-term consequences.

Conclusions: During a 4-year period in more than 3000 patients, no unanticipated MSAD complications have emerged, and there is no data to suggest a trend of increased events over time. The presentation and management of device-related issues have been less complicated than revisions for laparoscopic fundoplication or other interventions for GERD. MSAD is considered safe for the widespread treatment of GERD.

Keywords: antireflux surgery, lower esophageal sphincter, gastroesophageal reflux disease, complications, safety, outcomes

Introduction

GASTROESOPHAGEAL REFLUX DISEASE (GERD) is the most prevalent gastrointestinal complaint in the United States and a significant risk factor for esophageal adenocar-

cinoma.^{1,2} Although proton pump inhibitors (PPIs) are highly effective at suppressing gastric acid production to lower esophageal pH and treat esophagitis, in many patients receiving medical therapy, the disease is not fully controlled.³ As a result, management of GERD often involves increasing

¹Esophageal Institute of Atlanta, Atlanta, Georgia.

²Minnesota Gastroenterology, Plymouth, Minnesota.

³Department of Surgery, Keck School of Medicine, USC, Los Angeles, California.

⁴SurgOne Foregut Institute, Englewood, CO.

⁵Department of Surgery, MGH, Boston, Massachusetts.

Study Highlights: Magnetic sphincter augmentation has been safely used in more than 3000 patients. Device-related complications are rare and benign. Management of device complications can be done laparoscopically or endoscopically.

the dose of PPIs and extending their use beyond current Food and Drug Administration (FDA) use parameters, subjecting patients to potentially new risks related to higher doses and continuous use of PPIs.^{4–6} The historically employed surgical treatment, laparoscopic fundoplication (LF), is generally effective, but has significant side effects and a progressive rate of failure over time.⁷ Revisional surgery is required in up to 10%–15% of patients undergoing LF, and these reoperations carry significant risk and morbidity.^{8,9} The surgical alternative to LF is magnetic sphincter augmentation of the lower esophageal sphincter. The magnetic sphincter augmentation device (MSAD) is the only antireflux intervention to mechanically restore competency to the lower esophageal sphincter without alteration of the gastric fundus, providing a less invasive treatment option for restoring the barrier function of the gastroesophageal junction (GEJ).¹⁰ Since the first implant procedure nearly a decade ago, MSAD has maintained an excellent safety and efficacy profile.^{11,12} Nonetheless, there has been caution around the risk of device erosions after MSAD, largely borne from the past experiences of earlier devices, such as the Angelchik prosthesis.¹³

The Angelchik device came and went more than 30 years ago, but its reputation of device erosions and migrations continues to be a source of criticism for any device placed at the GEJ. MSAD is an example of how past limitations can be overcome by medical innovation. The MSAD was specifically engineered to be different than other implantable devices in this anatomic region.¹⁴ In contrast to the Angelchik device, MSAD has relatively no bulk, uses independent beads to create a very pliable, flexible, and expansible implant, and allows normal physiological motion of the esophagus. The MSAD is also individually sized to the diameter of the esophagus to be noncompressive to the esophageal wall.

Continued interest in the safety of MSAD is warranted based on its widespread use and adoption. The aims of this study include (1) reporting on the rate of device removals and erosions in the United States after FDA approval, (2) providing a risk-assessment framework for evaluating the clinical significance of complications, and (3) providing context of complications related to MSAD as compared with LF, which has historically been an accepted standard in antireflux surgery.

Methods

Events were collected from the Manufacturer and User Facility Device Experience (MAUDE) database, which houses medical reports submitted to the FDA of suspected device-associated deaths, serious injuries, and malfunctions.¹⁵ The authors also contacted the manufacturer for additional information, including the estimated number of implants performed in the United States, implant duration, and any events or relevant details not reported in the MAUDE database. The reporting period for this study was from March 22, 2012 (FDA approval) through May 31, 2016. Device removals were then categorized by reason for removal (dysphagia, persistent reflux symptoms, device erosion, magnetic resonance imaging, vomiting, and abdominal pain). Information collected for each event included the date of implant, the suspected reason for the event, the date and type of intervention required to address the event, and any complication related to the management of the event. The events

were summarized by time from implant to device removal (<1 year after implant, 1–2-years after implant, and >2 years after implant). In addition, to draw conclusions about the overall risk profile of the device and implant procedure, the events associated with the MSAD were evaluated by the following criteria: (1) the frequency of the complication/failure, (2) the clinical presentation of the complication/failure, (3) the clinical severity of the complication/failure, and (4) the complexity of management of the complication/failure.

Results

During the study period, 3283 patients were implanted with the MSAD at 165 institutions by 191 surgeons. The median implant duration for the study cohort was 1.4 years, with 1016 patients having an implant duration >2 years (Table 1). No perioperative deaths and life-threatening complications were reported. Over the entire period studied, no patient died as a result of the implant procedure or MSAD, and no device malfunctions or unanticipated events were reported.

The overall rate for device removal was 2.7% (89/3283) (Table 2). All device removals were performed electively through a laparoscopic or, in the case of device erosion, endoscopic approach without complications. The most common reason for device removal was dysphagia (52/89, 58.4%) and persistent reflux symptoms (19/89, 21.3%). Device removal for erosion and migration was 0.15% (5/3283) and 0% (0/3283), respectively. There were no perforations. The majority (51/89) of device removals occurred during the 1-year period after implant (Figs. 1 and 2). The rate of device removal and erosion in patients with an implant duration >2 years were 1.1% (11/1016) and 0.1% (1/1016), respectively.

Five device erosions occurred, for a rate of 0.15% (5/3283) (Table 3). All patients presented nonemergently with new dysphagia or odynophagia. No patient presented with abdominal pathology, specifically there was no peritonitis or evidence of intra-abdominal perforation. Median implant duration was 16 months (range 12–32 months), and device erosion was confirmed by endoscopic observation of magnetic beads in the esophageal lumen. All devices were removed by either endoscopic approach or a combination of laparoscopic and endoscopic techniques, with no complications or clinical consequences, regardless of the approach used for device removal.

Discussion

The analysis presented herein supplements previous safety reports on magnetic sphincter augmentation with a larger cohort

TABLE 1. SUMMARY OF CLINICAL EXPERIENCE DURING REPORTING PERIOD

Number of patients	3283
Number of implanting centers	165
Number of implanting surgeons	191
Median implant duration (years)	1.4
Number of patients by implant duration	
<1 year	1281
1–2 years	986
>2 years	1016

TABLE 2. RATE OF DEVICE REMOVALS

Reason for removal	Number of removals	Overall rate ^a , %
Dysphagia	52	1.6
GERD	19	0.6
Abdominal pain	4	0.1
Erosion	5	0.15
Other	5	0.15
Subsequent MRI	3	0.09
Vomiting	1	0.03
Total	89	2.7

^aNumber of patients with device removal divided by total patient population from reporting period ($N=3283$).

GERD, gastroesophageal reflux disease; MRI, magnetic resonance imaging.

of patients with longer implant duration.¹² The potential risk of device-related complications such as migration or erosion has been an ongoing concern that is now addressed based on the safety data reported herein and an understanding of how the design of the MSAD inherently minimizes these risks.

A previously published safety analysis of 1048 MSAD implants worldwide through July 2013 was published in 2014,¹² and at a median follow-up of 0.75 years (range 2–2302 days) in 700 patients, there was a negligible erosion rate of 0.2%, a removal rate of 4.6%, and no device migration or device failures. In this updated series covering only U.S. implanted patients since FDA approval, of 3283 implants with a median implant duration of 1.4 years (range 2 days to 4.1 years), the erosion rate decreased to 0.15%, the device removal rate decreased to 2.7% overall, and there remained no device migrations or failures. In the 1016 patients with an implant for more than 2 years, there were only 11 device removals, a removal rate of 1.1% (11/1016), representing only 12.4% (11/89) of removals overall. This establishes that over time there is not an escalating rate of removals or problems with the device. In addition, no new patterns of failure or complication have been seen, indicating a very stable and predictable rate and pattern of failure/removal, further confirming the safety of magnetic sphincter augmentation.

Although the rate of removal and erosion is an important measure of device safety, more important is what happens when removal is necessary or erosion occurs. All device removals were undertaken electively, including those associated with erosions. All erosions presented nonacutely with either new onset dysphagia or painful swallowing. No patient presented with any systemic symptoms or intra-abdominal pathology; in particular, there were no cases of intra-abdominal perforation or peritonitis. This nonacute presentation is likely caused by tissue reaction (healing) that encapsulates the exterior of the device isolating the intraluminal erosion from the abdominal cavity. This benign presentation allowed elective endoscopy to easily identify the erosion. Such a presentation and management have been true for the world-wide experience with MSAD erosions, including those not included in the U.S. cohort being presented here. In each of these erosions, the presentation was not acute or life threatening and the problem was diagnosed with an esophagogastroduodenoscopy (EGD) to observe the mucosa and inner lining of the esophagus. Once identified, the erosion could be managed electively through an endoscopic and/or laparoscopic approach for device removal without the need for significant corrective measures such as resection or reconstruction of the esophagogastric junction. No patient has suffered any permanent long-term problem from either the need for removal or the removal procedure. When indicated, patients proceed with fundoplication or other antireflux interventions without restriction.¹⁶ This pattern of device-related complications compares very favorably with recently introduced endoluminal approaches to GERD such as Stretta (Mederi Therapeutics, Inc., Norwalk, CT) or transoral intraluminal fundoplication (Endogastric Solutions, Redmond, WA), whereby serious morbidity such as esophageal perforation and significant bleeding have been reported.^{17–21}

It is instructive to consider how the MSAD differs from other implants at or near the GEJ that have historically had much higher complication rates. Older devices that were designed to improve lower esophageal sphincter (LES) function, such as the Angelchik device, had design features very different than those of the MSAD.^{22–24} The Angelchik device comprised an elastomer shell filled with silicone and

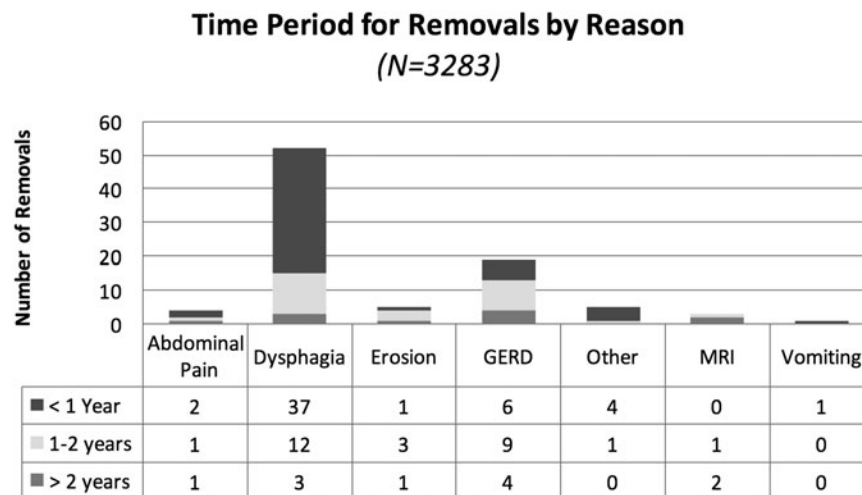


FIG. 1. Time from implant procedure to device removal by reason. GERD, gastroesophageal reflux disease; MRI, magnetic resonance imaging.

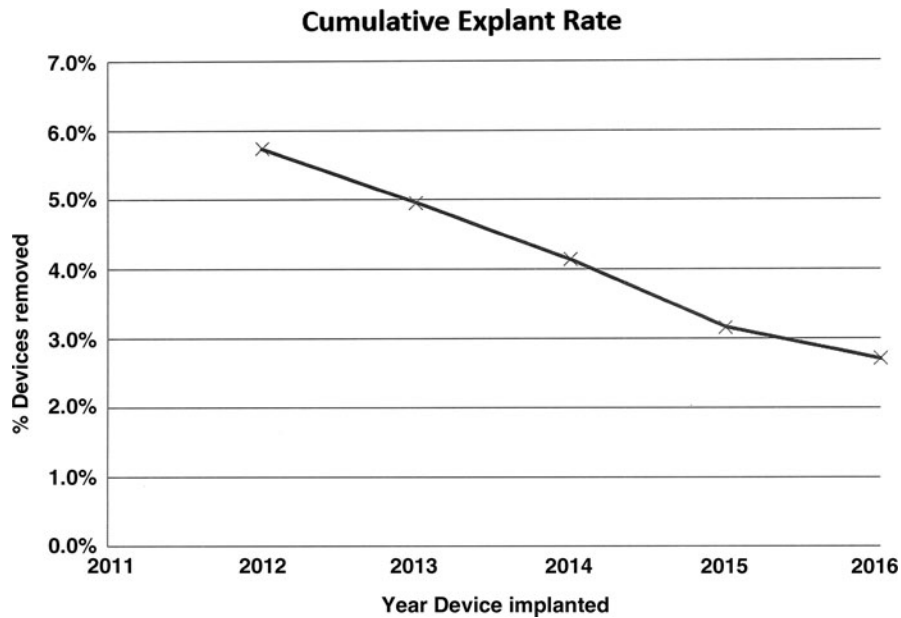


FIG. 2. Graph of frequency of device removal by year.

rimmed with a woven lace used to tie the device around the esophagus. This device augmented the reflux barrier with bulk, a rigid design, and a fixed diameter around the esophagus. The volume of the Angelchik device was ~ 50 mL, and the rigidity of the device and fixed diameter allowed for little or no device distention with food bolus transit. As a result of the non-conforming design around the GEJ, the erosion and migration rate for the Angelchik device were unacceptably high (5%–19%) and typically occurred within 1–2 years after implant.^{22–24}

The MSAD is specifically designed to mitigate these complications. Compared with the Angelchik device, the MSAD comprises connected magnetic cores encased in medical grade titanium, an inert and biostable material. MSAD augments the reflux barrier by magnetic force, not bulk as with the Angelchik device. The MSAD is small with only 1.2 mL of volume (Fig. 3),¹⁴ and variable diameters of the device allow it to be sized to fit each patient's esophageal diameter, thereby allowing the device to be placed in a noncompressive, neutral position around the esophagus. The forces of magnetic attraction between beads and the neutral

positioning of the device around the esophagus augment the yield pressure of the LES without the need for tissue compression or compromise. For the LES to open to allow a pathological reflux event to occur, both the LES and the magnetic force of the MSAD's augmentation need to be overcome. The device, however, is able to open in response to pressure to allow food bolus transit and normal physiological functions such as belching and vomiting. Importantly, and compared with other devices, the design of the MSAD minimizes the effects and forces of the device directly on the esophagus, thereby eliminating tissue compression and damage, which explains the low rate of problems related to the device and erosion.

Rates of erosion and migration complications after magnetic sphincter augmentation compare very favorably with the most common surgical treatment of GERD today, esophagogastric fundoplication, whereby fundoplication-related complications such as suture or pledget erosion, wrap migration with resulting severe anatomic distortion, vagal nerve damage,²⁵ or failure requiring reoperation occur in up to 20%

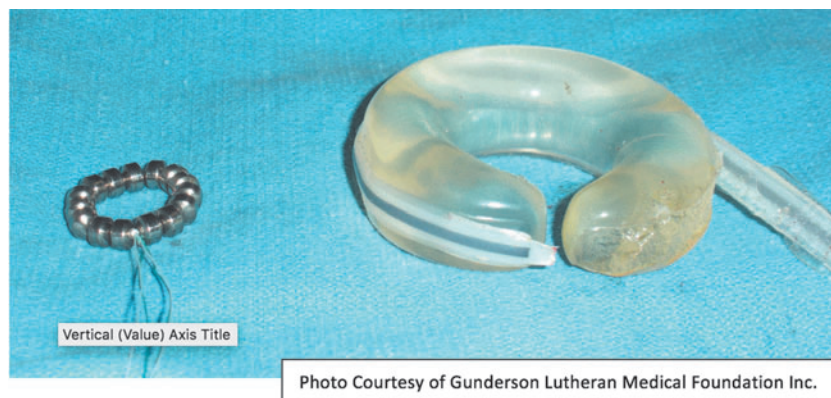

FIG. 3. Comparison of Angelchik device and magnetic sphincter augmentation device.

TABLE 3. EROSIONS

<i>Erosion event</i>	<i>Age (years)</i>	<i>Gender</i>	<i>Device size (number of beads)</i>	<i>Presenting symptoms</i>	<i>Implant duration (months)</i>	<i>Removal method</i>
1	58	Male	14	Dysphagia and epigastric discomfort	14	1
2	49	Male	12	Dysphagia after an episode of wrenching/vomiting when prepping for a colonoscopy	22	2 ^a
3	66	Male	13	Dysphagia, chest pain and return of LPR symptoms	16	3
4	55	Female	12	Dysphagia	12	3
5	39	Male	14	Dysphagia	32	3

^aPatients also underwent Toupet procedure at time of device removal.

1 = endoscopic removal of beads in the esophageal lumen followed at a later date by laparoscopic removal of remaining beads around the external esophagus; 2 = combined endoscopic and laparoscopic device removal during the same procedure; 3 = device removed entirely by endoscopic approach during a single procedure.

LPR, laryngopharyngeal reflux.

of patients.²⁶ Failure after fundoplication is also progressive and often requires reoperation. Compared with failure and reoperation after fundoplication, early experience suggests that it is both more difficult and more morbid to redo a failed fundoplication that has migrated or herniated than to remove an MSAD and construct a new fundoplication. The surgeon authors of this article have experience with both, and there is no question in our minds that removal of the MSAD is far more benign than revisional fundoplication surgery. In a review article of risks for surgical reintervention of fundoplication, Furnee et al. reported an intraoperative complication rate of 21.4% and a postoperative complication rate of 15.6%.²⁷ The success rate of the redo procedure was limited to 65%–70%. Some fundoplication patients have required major resection with Roux-en-Y esophagostomy reconstruction and even esophagectomy. To date, the likelihood of erosion after MSAD is 0.15%, there has not been an observed compounding rate of erosions over time, and management has to date not required a major resection or resulted in long-term disability or problems. The same has been true for device removal for all causes.

This research suffers from the retrospective, self-reported nature of the MAUDE database and company source data. It is possible, in fact likely, that there are cases of removal not included in this data set. That acknowledged, we believe that the number of under-reported cases to be very low. There are several reasons for this belief. First, surgeons trained and approved to implant the Linx device must agree to report to the company any and all device-related complications, especially device removals. It is very unlikely that a Linx implanting surgeon will have encountered an erosion or performed a device removal without notifying the company. Next, the company maintains a very active team of sales and account representatives who are constantly in communication with each account about any Linx patient issues and complications. Finally, it is typical of new technology that any device-related complication is broadcast through communications with colleagues and case reports about the complication or event. For these reasons, we believe the data presented here are as accurate as can be achieved with a new device introduction to broad clinical use.

In conclusion, based on extensive clinical experience over a 4-year period with more than 3000 patient implants, we believe we now have further understanding of safety after

MSAD. In this follow-up period, no unanticipated complications have emerged and there is no clinical data to suggest a trend of increased events at later time points after implant. Clinically, the presentation and management of device removals and erosions have been less complicated than revisions for LF. With a low rate of device removals, rare occurrence of device erosions, and benign presentation and management, the clinical evidence supports MSAD as safe for the widespread treatment of GERD.

Acknowledgment

None.

Disclosure Statement

Drs. C.D.S., J.C.L., and R.C.B. received consulting and research funding from Torax Medical.

References

- Everhart J, Ruhl CE. The burden of digestive diseases in the United States Part I: Overall and upper gastrointestinal diseases. *Gastro* 2009;136:376–386.
- Lagergren J, Bergstrom R, Lindgren A, Nyren O. Symptomatic gastroesophageal reflux as a risk factor for esophageal adenocarcinoma. *N Engl J Med* 1999;340:825–831.
- Dicman R, Maradey-Romero C, Gingold-Belfer R, Fass R. Unmet needs in the treatment of gastroesophageal reflux disease. *J Neorogastroenterol Motil* 2015;21:309–319.
- Abramowitz J, Thakkar P, Isa A, Truong A, Park C, Rosenfeld RM. Adverse event reporting for proton pump inhibitor therapy: An overview of systematic reviews. *Otolaryngol Head Neck Surg* 2016;155:547–554.
- Lazarus B, Chen Y, Wilson FP, Sang Y, Chang AR, Coresh J, Grams ME. Proton pump inhibitor use and the risk of chronic kidney disease. *JAMA Internal Medicine* 2016;176:238–246.
- Gomm W, von Holt K, Thome F, Broich K, Maier W, Fink A, Doblhammer G, Haenisch B. Association of proton pump inhibitors with risk of dementia: A pharmacoepidemiological claims data analysis. *JAMA Neurol* 2016;73:410–416.
- Richter JE. Gastroesophageal reflux disease treatment: side effects and complications of fundoplication. *Clin Gastroenterol Hepatol* 2013;11:465–471.

8. Drassisam WA, et al. Five-year subjective and objective results of laparoscopic and conventional Nissen fundoplication: A randomized trial. *Ann Surg* 2006;244:33–411.
9. Lafullarde T, et al. Laparoscopic Nissen fundoplication: Five-year results and beyond. *Arch Surg* 2001;136:180–184.
10. Ganz RA, Edmundowicz SA, Taiganides PA, Lipham JC, Smith CD, DeVault KR, Horgan S, Jacobsen G, Luketich JD, Smith CC, Schlack-Haerer SC, Kothari SN, Dunst CM, Watson TJ, Peters J, Oelschlagel BK, Perry KA, Melvin S, Bemelman WA, Smout AJ, Dunn D. *Clin Gastroenterol Hepatol* 2016;14:671–677.
11. Saino G, Bonavina L, Lipham JC, Dunn D, Ganz RA. Magnetic sphincter augmentation for gastroesophageal reflux at 5 years: Final results of a pilot study show long-term acid reduction and symptom improvement. *J Laparoendosc Adv Surg Tech A* 2015;25:787–792.
12. Lipham JC, Taiganides PA, Louie BE, Ganz RA, DeMeester TR. Safety analysis of first 1000 patients treated with magnetic sphincter augmentation for gastroesophageal reflux disease. *Dis Esophagus* 2015;28:305–311.
13. Bielefeldt K. Adverse events after implantation of a magnetic sphincter augmentation device for gastroesophageal reflux. *Clin Gastroenterol Hepatol* 2016;14:1507–1508.
14. Ganz R, Gostout C, Grudem J, et al. Use of a magnetic sphincter for the treatment of GERD: A feasibility study. *Gastrointest Endosc* 2008;67:287–294.
15. Manufacturer and User Facility Device Experience (MAUDE) Database. www.accessdata.fda.gov/scripts/cdrh/cfdocs/cfMAUDE/Search.cfm?smc=1 (accessed June 6, 2016).
16. Asti E, Siboni S, Lazzari V, Bonitta G, Sironi A, Bonavina L. Removal of the magnetic sphincter augmentation device. *Ann Surg* 2017;265:941–945.
17. Hoppo T, Immanuel A, Schuchert M, et al. Transoral incisionless fundoplication 2.0 procedure using EsophyX™ for gastroesophageal reflux disease. *J Gastrointest Surg* 2010;14:1895–1901.
18. Witterman B, Strijkers R, de Vries E, et al. Transoral incisionless fundoplication for treatment of gastroesophageal reflux disease in clinical practice. *Surg Endosc* 2012;26:3307–3315.
19. Muls V, Eckhardt AJ, Marchese M, et al. Three-year results of a multicenter prospective study of transoral incisional fundoplication. *Surg Innov* 2013;20:321–330.
20. Demyttenaere SV, Bergman S, Pham T, Anderson J, Detorre R, Melvin WS, Mikami DJ. Transoral incisionless fundoplication for gastroesophageal reflux disease in an unselected patient population. *Surg Endosc* 2010;24:854–858.
21. Lipka S, Kumar A, Richter JE. No evidence for efficacy of radiofrequency ablation for treatment of gastroesophageal reflux disease: A systematic review and meta-analysis. *Clin Gastroenterol Hepatol* 2015;13:1058–1067.
22. Kozarek R, Brayko C, Sanowski R, et al. Evaluation of the Angelchik antireflux prosthesis: Long-term results. *Dig Dis Sci* 1985;30:723–732.
23. Maxwell-Armstrong CA, Steele RJ, Amar SS, et al. Long-term results of the Angelchik prosthesis for gastro-esophageal reflux. *Br J Surg* 1997;84:862.
24. Thibault C, Marceai P, Biron S, Bourque RA, Beland L, Potvin M. The Angelchik antireflux prosthesis: Long-term clinical and technical follow-up. *Can J Surg* 1994;37:12–17.
25. Rijn S, van Rinsma NF, van Herwaarden-Lindeboom MYA, Ringers J, Gooszen HG, van Rijn PJJ, Veenendaal RA, Conchillo JM, Bouvy ND, Masclee AAM. Effect of vagus nerve integrity on short and long-term efficacy of antireflux surgery 2016;111:508–515.
26. Symons NR, Purkayastha S, Dillemans B, et al. Laparoscopic revision of failed antireflux surgery: A systematic review. *Am J Surg* 2011;202:336–343.
27. Furnee JB, Draaisma WA, Broeders IAMJ, et al. Surgical reintervention after failed antireflux surgery: A systematic review of the literature. *J Gastrointest Surg* 2009;13:1539–1549.

Address correspondence to:

C. Daniel Smith, MD

Esophageal Institute of Atlanta

2045 Peachtree Road, Suite 310

Atlanta, GA 30309

E-mail: cdsmith@esophageal.institute