



# Worldwide Experience with Erosion of the Magnetic Sphincter Augmentation Device

Evan T. Alicuben<sup>1</sup> · Reginald C. W. Bell<sup>2</sup> · Blair A. Jobe<sup>3,4</sup> · F. P. Buckley III<sup>5</sup> · C. Daniel Smith<sup>6</sup> · Casey J. Graybeal<sup>7</sup> · John C. Lipham<sup>1</sup>

Received: 31 January 2018 / Accepted: 3 April 2018  
© 2018 The Society for Surgery of the Alimentary Tract

## Abstract

**Background** The magnetic sphincter augmentation device continues to become a more common antireflux surgical option with low complication rates. Erosion into the esophagus is an important complication to recognize and is reported to occur at very low incidences (0.1–0.15%). Characterization of this complication remains limited. We aim to describe the worldwide experience with erosion of the magnetic sphincter augmentation device including presentation, techniques for removal, and possible risk factors.

**Materials and Methods** We reviewed data obtained from the device manufacturer Torax Medical, Inc., as well as the Manufacturer and User Facility Device Experience (MAUDE) database. The study period was from February 2007 through July 2017 and included all devices placed worldwide.

**Results** In total, 9453 devices were placed and there were 29 reported cases of erosions. The median time to presentation of an erosion was 26 months with most occurring between 1 and 4 years after placement. The risk of erosion was 0.3% at 4 years after device implantation. Most patients experienced new-onset dysphagia prompting evaluation. Devices were successfully removed in all patients most commonly via an endoscopic removal of the eroded portion followed by a delayed laparoscopic removal of the remaining beads. At a median follow-up of 58 days post-removal, there were no complications and 24 patients have returned to baseline. Four patients reported ongoing mild dysphagia.

**Conclusions** Erosion of the LINX device is an important but rare complication to recognize that has been safely managed via minimally invasive approaches without long-term consequences.

**Keywords** Magnetic sphincter augmentation device · Gastroesophageal reflux disease · Esophageal erosion

---

Meeting Presentation: This work was not presented at a meeting.

---

✉ John C. Lipham  
john.lipham@med.usc.edu

- <sup>1</sup> Department of Surgery, Keck Medicine of USC, University of Southern California, 1510 San Pablo St. #514, Los Angeles, CA 90033, USA
- <sup>2</sup> SurgOne Foregut Institute, Englewood, CO, USA
- <sup>3</sup> Esophageal and Lung Institute, Allegheny Health Network, Pittsburgh, PA, USA
- <sup>4</sup> Temple University School of Medicine, Philadelphia, PA, USA
- <sup>5</sup> Foregut & Reflux Surgery, Dell Medical School, The University of Texas-Austin, Austin, TX, USA
- <sup>6</sup> Esophageal Institute of Atlanta, Atlanta, GA, USA
- <sup>7</sup> The Heartburn and Swallowing Center, Northeast Georgia Physicians Group, Gainesville, GA, USA

## Introduction

The surgical management of acid reflux has largely been via the fundoplication. Magnetic sphincter augmentation of the lower esophageal sphincter (LES) was developed as an alternative. The LINX Reflux Management System (Torax Medical), first used in February 2007 as part of a clinical trial, is a string of magnetic beads that is placed around the esophagus to augment the weak LES.<sup>1</sup> It received FDA approval in March 2012.<sup>2</sup> The force of attraction of the magnetic beads increases the yield pressure of the LES while also being able to expand with increases in intraluminal pressure. This dynamic function allows for swallowing while also preserving the ability to belch and vomit. Long-term studies have demonstrated its clinical efficacy as an anti-reflux barrier.<sup>3–5</sup>

There have been previous reports which have discussed the safety profile of the magnetic sphincter augmentation device.

A large published series found complication rates to be low among the first 1000 treated patients.<sup>6</sup> The most unique complication of this procedure is device erosion. Erosion into the esophagus was reported in this series as occurring in one patient (0.1%). Since then, other reports have emerged describing isolated cases of erosion and their management.<sup>7–10</sup> Recently, based on an updated data series, the erosion rate in 3283 patients was found to be 0.15%.<sup>11</sup> All devices were successfully removed without complication. Nevertheless, characterization of this complication remains limited.

We aim to describe the worldwide experience with erosion of the magnetic sphincter augmentation device including presentation, techniques for removal, and possible risk factors.

## Materials and Methods

A retrospective review was performed on data available for all patients who underwent placement of a magnetic sphincter augmentation device from February 2007 through July 2017. The dataset was obtained from the device manufacturing company Torax Medical, Inc. (Shoreview, MN) who keeps a prospectively maintained database of devices placed worldwide. Additionally, events from the Manufacturer and User Facility Device Experience (MAUDE) database were reviewed. The MAUDE database is maintained by the Food and Drug Administration and includes all potential device related complications. Data from the MAUDE database cannot be used to generate adverse event rates and thus were used only to identify patients that may not have been included in the dataset obtained from Torax Medical. The risk of erosion over time was determined via Kaplan-Meier method.

This study was approved by the Institutional Review Board of the University of Southern California.

## Results

There were 9453 devices placed through July 2017. There have been 29 reported cases of erosions. Smaller devices were more commonly associated with erosion with 12-bead devices having a 4.93% erosion rate (Table 1).

Most patients with erosions presented between 1 and 4 years after device implantation with few presenting within the first year (Fig. 1). The median time to erosion was 26 months. The most common presenting symptom was dysphagia in 26 patients (90%) followed by chest pain in 7 patients. Other less common symptoms included reflux, coughing, vomiting, and weight loss.

The risk of erosion over time was determined (Fig. 2). At 1 year after implantation, the erosion risk was 0.05%. This gradually increased to 0.3% at 4 years.

**Table 1** Erosion rate by device size

Device size	Total implanted	Number of erosions	Erosion rate (%)
12	365	18	4.93
13	1960	6	0.31
14	2723	4	0.15
15	2277	1	0.04
16	1448	0	0.00
17	674	0	0.00

Most devices were removed via endoscopic removal of the eroded portion first, followed by a delayed laparoscopic removal of the remainder of the device (Table 2). Nine devices were removed entirely via an endoscopic approach alone. Five were removed via a single-stage combined endoscopic/laparoscopic approach. Other techniques included a single-stage laparoscopic removal and a laparoscopic transgastric approach.

All devices were removed without complication. At a median follow-up of 58 days (1.9 months), 24 patients have returned to baseline and are symptom free. Four patients reported mild dysphagia and two patients have mild odynophagia.

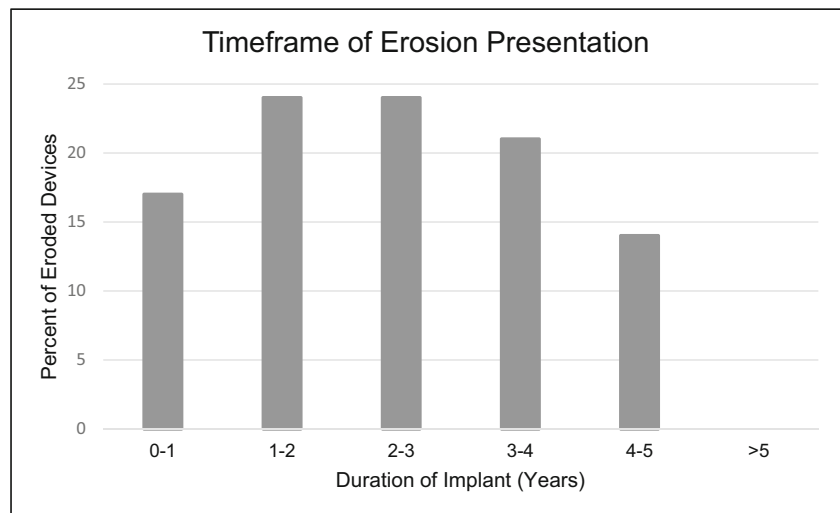
## Discussion

Erosion of the LINX device is an important complication to recognize and manage. Given the purpose of the LINX device and its conceptual similarity to the now historic Angelchik device, there have been concerns about the possibility of erosion. The Angelchik device was a much larger, rigid device that had issues with migration as well as erosion.<sup>12,13</sup> Long-term studies revealed a migration rate of 8.6–9.2% and an erosion rate of 1.5–3.4%. The LINX, on the other hand, is a much smaller, dynamic device that has had no reported issues with migration and a significantly lower erosion rate. The available worldwide data confirm that this is an uncommon complication with an estimated erosion rate between 0.1 and 0.4% to date. All devices were successfully removed through minimally invasive strategies. In previously published cases, all patients have made uneventful recoveries and none have required esophageal or gastric resection. This remained true for this series of all reported erosions worldwide.

## Presentation

When a device erosion occurs, patients usually present years after placement with new onset of dysphagia or chest pain. Diagnostic evaluation should include a radiographic swallow study to evaluate the position of the device as well as for assessment of esophageal motility and possible hiatal hernia. Interestingly, all of the published cases describe narrowing at

**Fig. 1** Bar plot representing distribution of eroded devices by length of implant. Most patients presented between 1 and 4 years after implantation



the area of the device but none have had evidence of contrast extravasation or erosion.<sup>7,9</sup> This suggests that the esophageal defect created by the erosion is likely contained and sealed by the capsule around the beads thereby preventing extravasation or esophageal leakage. Esophagram has, therefore, not been diagnostic of an erosion but helps rule out other reasons for dysphagia. An esophagogastroduodenoscopy is the seminal test and will reveal intraluminally exposed beads as a result of the erosion into the esophagus. Most patients were found to have 2–4 intraluminal beads (Fig. 3). There are no reports of circumferential or near circumferential erosion.

**Risk Factors**

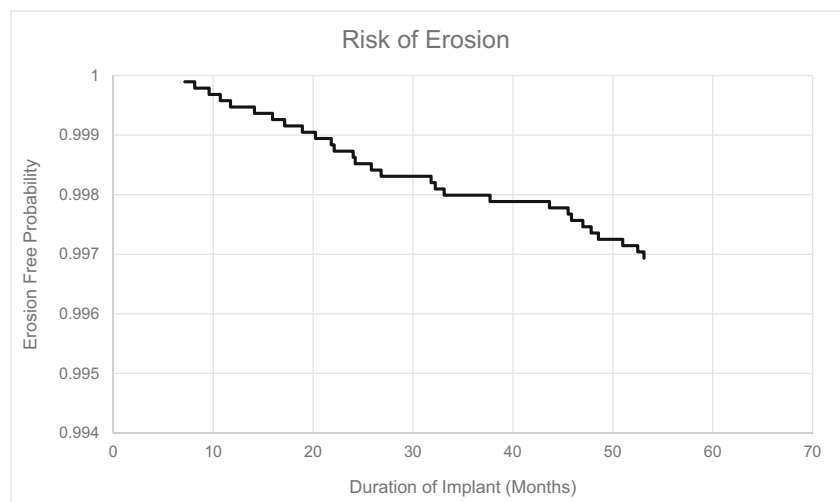
There are proposed risk factors for development of erosion. Further attention to these may help to minimize this complication in future patients.

**Size Mismatch/Undersizing**

The most likely contributory factor is undersizing the device, making it compressive around the lower esophageal sphincter. The device was designed to resist opening of the LES thereby increasing the yield pressure. It was not intended to be compressive and additional resting tension of the device does not increase its efficacy.

In this series, smaller devices were associated with higher rates of erosion. Additionally, in centers that had the highest reported rate of implanting smaller size devices, they experienced an erosion rate 4–20 times higher than others. At these centers, it was thought that sizing smaller would result in better reflux control. This belief was not shared by other centers where devices were generally sized larger and erosion rates were lower. Furthermore, it is notable that the 12-bead device, which was responsible for 18/29 (62%) of erosions, is no longer available for implantation. Due to this, we anticipate

**Fig. 2** Kaplan-Meier curve demonstrating risk of esophageal erosion over time



**Table 2** Various techniques utilized for device removal

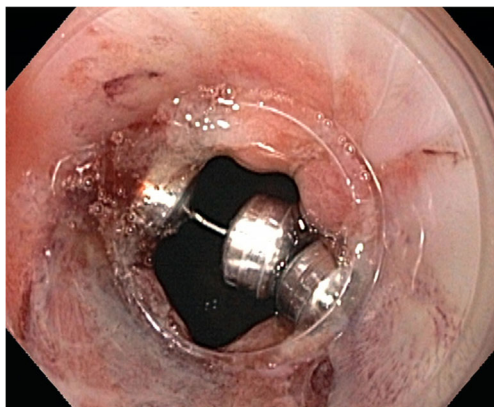
Technique	Number of cases
Endoscopic partial removal with delayed laparoscopic removal	12
Endoscopic only	9
Single-stage combined endoscopic/laparoscopic	5
Laparoscopic only	2
Transgastric approach	1

that the erosion rate will become lower as more larger-sized devices are placed.

Erosions also occurred with larger devices emphasizing the importance of proper sizing. To obtain the optimal size, we utilize two visual cues. First, a sizing device is placed around the esophagus and the proper size is where the sizer rests comfortably around the esophagus without compression. The second visual cue is obtained by continuing to ratchet down the sizer until it releases from encircling the esophagus. Two sizes above this release size are usually appropriate. The two sizing methods are then compared. If they do not correlate, the larger size is selected.

### Infection

Similar to other implanted devices, the magnetic sphincter is susceptible to infection. Once inoculated, it is very unlikely that bacteria will clear. Inflammation and smoldering infection may produce localized tissue necrosis and resulting erosion. Unfortunately, cultures of explanted devices are of little clinical utility as exposure to upper gastrointestinal intraluminal bacteria makes it impossible to delineate the true infectious source. Minimal handling of the device once outside of sterile packaging and immediate insertion into the body may reduce this risk.



**Fig. 3** Endoscopic view of eroded beads. When put on tension, the wire in between two beads becomes visible

### Extent of Hiatal Dissection

Surgical technique may also play a role. This is especially important in patients with larger hiatal hernias and those undergoing redo surgery as additional dissection is performed placing the esophagus at increased risk for unrecognized injury. Early techniques utilized a minimal dissection to create a posterior window to facilitate placement of the device. This may have increased the risk of damage to the posterior esophageal wall due to limited visibility. Currently, a full hiatal dissection has been adopted which gives better exposure and allows fully addressing the crura as an essential element of the GERD barrier.

### Patient-Specific Risk Factors

There are undoubtedly other possible risk factors for development of esophageal erosion. While this study has focused on device and surgery-specific factors, it is important to consider patient specific factors that may predispose to tissue weakening, such as connective tissue disorders, and breakdown, such as steroid use, poorly controlled diabetes, and immunosuppression. Acknowledging these may have a role in preoperative patient counseling.

### Removal Techniques

There are multiple described techniques for removal of the LINX device. The most common approach in cases of erosion has been endoscopic removal of any visible beads with staged laparoscopic removal. We recommend starting with an endoscopic approach as this is less invasive, and many devices can be completely removed with this strategy alone. If not possible, the visible beads can be removed endoscopically with a staged laparoscopic removal of the remaining beads 6–8 weeks later. This may allow the eroded area to heal and local infection to clear which should facilitate an easier laparoscopic removal.

There have been multiple endoscopic approaches described that have been successful in removing the entire device endoscopically.<sup>7,10</sup> An upper endoscopy is first performed confirming presence of the erosion. Once visualized, an endoscopic cutting device is used to divide the wire in between two visible beads. Most centers have used the Olympus Endoloop Cutter (Olympus Medical Systems). A grasping device then extracts the string of beads through the esophageal defect. In most cases, the esophageal defect is left to heal; however, some centers have described placing endoscopic clips to close the defect.

It is important to note that the LINX device is a series of magnetic beads with each pair connected by an individual posted wire as opposed to one continuous wire running



through all of the beads. Therefore, when a wire is cut, only the two adjacent beads will separate. The device can then be removed without risk of detaching other beads. An important caveat is that the most widely available cutting device is able to transect through only older versions of the device made to be MRI compatible up to 0.7 T. Newer versions have since been manufactured to tolerate a 1.5-T MRI. These devices have a stronger, alloyed wire which is not able to be cut with the Olympus Endoloop Cutter. A new endoscopic cutting tool is in development.

A possible solution involves use of a harmonic scalpel to endoscopically cut the wire, which was performed in one patient in this series. A bariatric length harmonic scalpel was placed through suction tubing to protect the device jaws. The protected device was advanced to the gastroesophageal junction alongside a pediatric endoscope allowing for direct visualization. The tubing was retracted exposing the jaws which were then used to cut through the exposed wire. Both harmonic scalpel and pediatric endoscope were removed and exchanged for a standard sized endoscope for device removal.

The most widely described removal technique across all implanted devices has been the laparoscopic approach. This technique has been employed mainly for non-eroded devices but has been used in some cases of erosion as a single-stage procedure. Once pneumoperitoneum has been established, additional ports may be placed through the prior incisions. The fibrous capsule surrounding the device is then identified and opened with a monopolar device or scissors revealing the underlying beads. The wire connecting two of the beads is then cut with a harmonic scalpel and one of the beads is grasped. The device is then pulled out of the capsule. If not easily mobilized, additional portions of the capsule may be opened. Once removed, the number of beads should be confirmed with prior operative records and the device can be removed from the abdomen through a 10-mm port. After removal from the abdomen, intraoperative endoscopy should be performed to evaluate for any additional mucosal injuries created during the operation. In a recently published series, Asti et al. reported on their institutional experience with removal via a one-stage laparoscopic procedure demonstrating its safety.<sup>14</sup>

In one patient, the device was removed via a transgastric approach. Laparoscopic ports were placed directly into the stomach and the wire between two beads was cut with a harmonic scalpel. The device was pulled into the stomach and removed. Given the low number of reported cases, it is unknown which approach yields the best outcome and further study is warranted.

## Conclusions

Erosion of the LINX device is an important but rare complication to recognize. Most patients present with new-onset

dysphagia which should raise concern for this potential complication. Erosions have been safely managed via minimally invasive approaches with no patients requiring esophageal or gastric resection. Ongoing vigilance, especially in device sizing, hiatal dissection and maintaining sterile technique should minimize this rare complication.

**Author Contributions** Study conception and design: Lipham.

Acquisition, analysis, or interpretation of data: Alicuben, Bell, Jobe, Buckley, Smith, Graybeal, Lipham.

Drafting or critically revising: Alicuben, Bell, Jobe, Buckley, Smith, Graybeal, Lipham.

Final approval: Alicuben, Bell, Jobe, Buckley, Smith, Graybeal, Lipham.

## Compliance with Ethical Standards

**Grant Support** This work was completed without financial assistance.

**Meeting Presentation** This work was not presented at a meeting.

## References

1. Ganz RA, Peters JH, Horgan S, Bemelman WA, Dunst CM, Edmundowicz SA et al. Esophageal sphincter device for gastroesophageal reflux disease. *N Engl J Med*. 2013;368(8):719–27. <https://doi.org/10.1056/NEJMoa1205544>.
2. Reynolds JL, Zehetner J, Bildzukewicz N, Katkhouda N, Dandekar G, Lipham JC. Magnetic sphincter augmentation with the LINX device for gastroesophageal reflux disease after U.S. Food and Drug Administration approval. *Am Surg*. 2014;80(10):1034–8.
3. Ganz RA, Edmundowicz SA, Taiganides PA, Lipham JC, Smith CD, DeVault KR et al. Long-term Outcomes of Patients Receiving a Magnetic Sphincter Augmentation Device for Gastroesophageal Reflux. *Clin Gastroenterol Hepatol*. 2016;14(5):671–7. <https://doi.org/10.1016/j.cgh.2015.05.028>.
4. Bonavina L, Saino G, Bona D, Sironi A, Lazzari V. One hundred consecutive patients treated with magnetic sphincter augmentation for gastroesophageal reflux disease: 6 years of clinical experience from a single center. *J Am Coll Surg*. 2013;217(4):577–85. <https://doi.org/10.1016/j.jamcollsurg.2013.04.039>.
5. Warren HF, Reynolds JL, Lipham JC, Zehetner J, Bildzukewicz NA, Taiganides PA et al. Multi-institutional outcomes using magnetic sphincter augmentation versus Nissen fundoplication for chronic gastroesophageal reflux disease. *Surg Endosc*. 2016;30(8):3289–96. <https://doi.org/10.1007/s00464-015-4659-y>.
6. Lipham JC, Taiganides PA, Louie BE, Ganz RA, DeMeester TR. Safety analysis of first 1000 patients treated with magnetic sphincter augmentation for gastroesophageal reflux disease. *Dis Esophagus*. 2015;28(4):305–11. <https://doi.org/10.1111/dote.12199>.
7. Bauer M, Meining A, Kranzfelder M, Jell A, Schirren R, Wilhelm D et al. Endoluminal perforation of a magnetic antireflux device. *Surg Endosc*. 2015; 29(12):3806–10. <https://doi.org/10.1007/s00464-015-4145-6>.
8. Parmar AD, Tessler RA, Chang HY, Svahn JD. Two-Stage Explantation of a Magnetic Lower Esophageal Sphincter Augmentation Device Due to Esophageal Erosion. *J*

- Laparoendosc Adv Surg Tech A. 2017; 27(8):829–33. <https://doi.org/10.1089/lap.2017.0153>.
9. Salvador R, Costantini M, Capovilla G, Polese L, Merigliano S. Esophageal Penetration of the Magnetic Sphincter Augmentation Device: History Repeats Itself. *J Laparoendosc Adv Surg Tech A*. 2017; 27(8):834–8. <https://doi.org/10.1089/lap.2017.0182>.
  10. Yeung BPM, Fullarton G. Endoscopic removal of an eroded magnetic sphincter augmentation device. *Endoscopy*. 2017; 49(7):718–9. <https://doi.org/10.1055/s-0043-109236>.
  11. Smith CD, Ganz RA, Lipham JC, Bell RC, Rattner DW. Lower Esophageal Sphincter Augmentation for Gastroesophageal Reflux Disease: The Safety of a Modern Implant. *J Laparoendosc Adv Surg Tech A*. 2017; 27(6):586–91. <https://doi.org/10.1089/lap.2017.0025>.
  12. Maxwell-Armstrong CA, Steele RJ, Amar SS, Evans D, Morris DL, Foster GE et al. Long-term results of the Angelchik prosthesis for gastro-oesophageal reflux. *Br J Surg*. 1997; 84(6):862–4.
  13. Varshney S, Kelly JJ, Branagan G, Somers SS, Kelly JM. Angelchik prosthesis revisited. *World J Surg*. 2002; 26(1):129–33. <https://doi.org/10.1007/s00268-001-0192-3>.
  14. Asti E, Siboni S, Lazzari V, Bonitta G, Sironi A, Bonavina L. Removal of the Magnetic Sphincter Augmentation Device: Surgical Technique and Results of a Single-center Cohort Study. *Ann Surg*. 2017; 265(5):941–5. <https://doi.org/10.1097/SLA.0000000000001785>.